



## Summary Feedback

### ST1 – ST4 Teaching Programme 2023

### **FRCR 2B Viva - Breast Imaging (Session 21)**

**(8<sup>th</sup> June 2023)**

**Delivered By:**

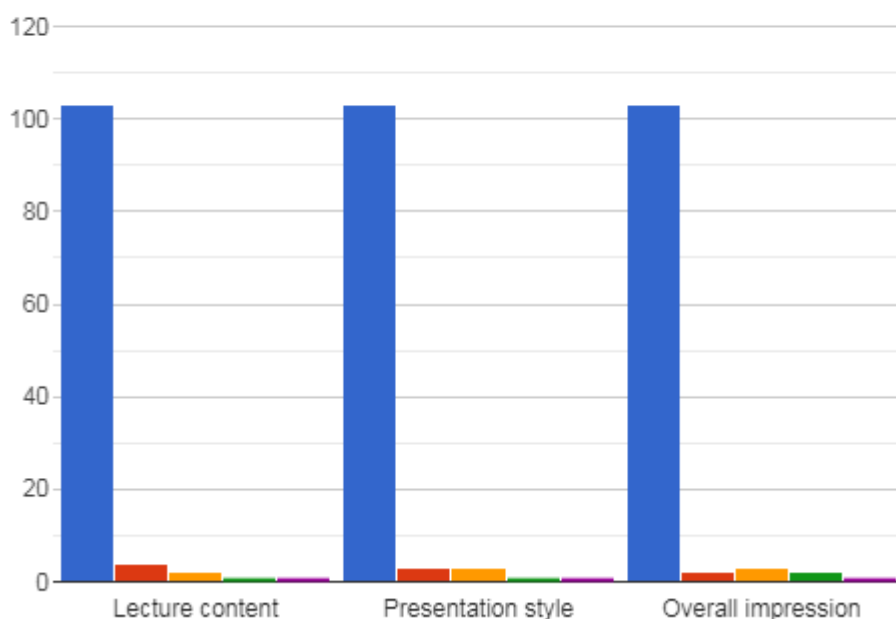
**(Muhammad Ahsan Saleem)**

#### Summary Points:

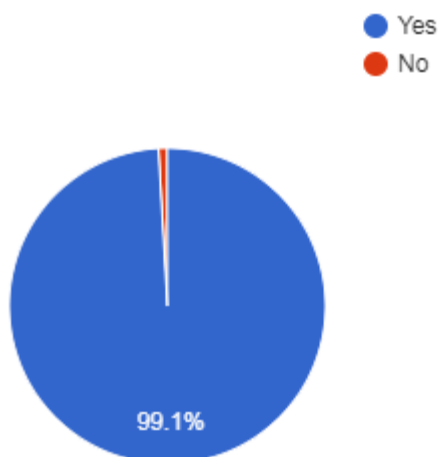
- ST1-ST4 teaching programme 2023 – FRCR 2B Practice Viva Session 21: 2 hours teaching time
- Total Attendees: 345 from 36 Countries (Australia, Bahrain, Bangladesh, Botswana, Brunei, Canada, China, Dominica, Egypt, Hong Kong, India, Indonesia, Iraq, Ireland, Jordan, Kenya, Kuwait, Malaysia, Mauritius, Myanmar, Nepal, New Zealand, Nigeria, Oman, Pakistan, Saudi Arabia, South Africa, Sri Lanka, Sudan, Swaziland, Türkiye, UAE, UK, Yemen, Zambia, Zimbabwe).
- Total feedback received from 111 participants

Please rate the following aspects of the session

Excellent    Very good    Good    Satisfactory  
Poor



Did you find it useful  
111 responses



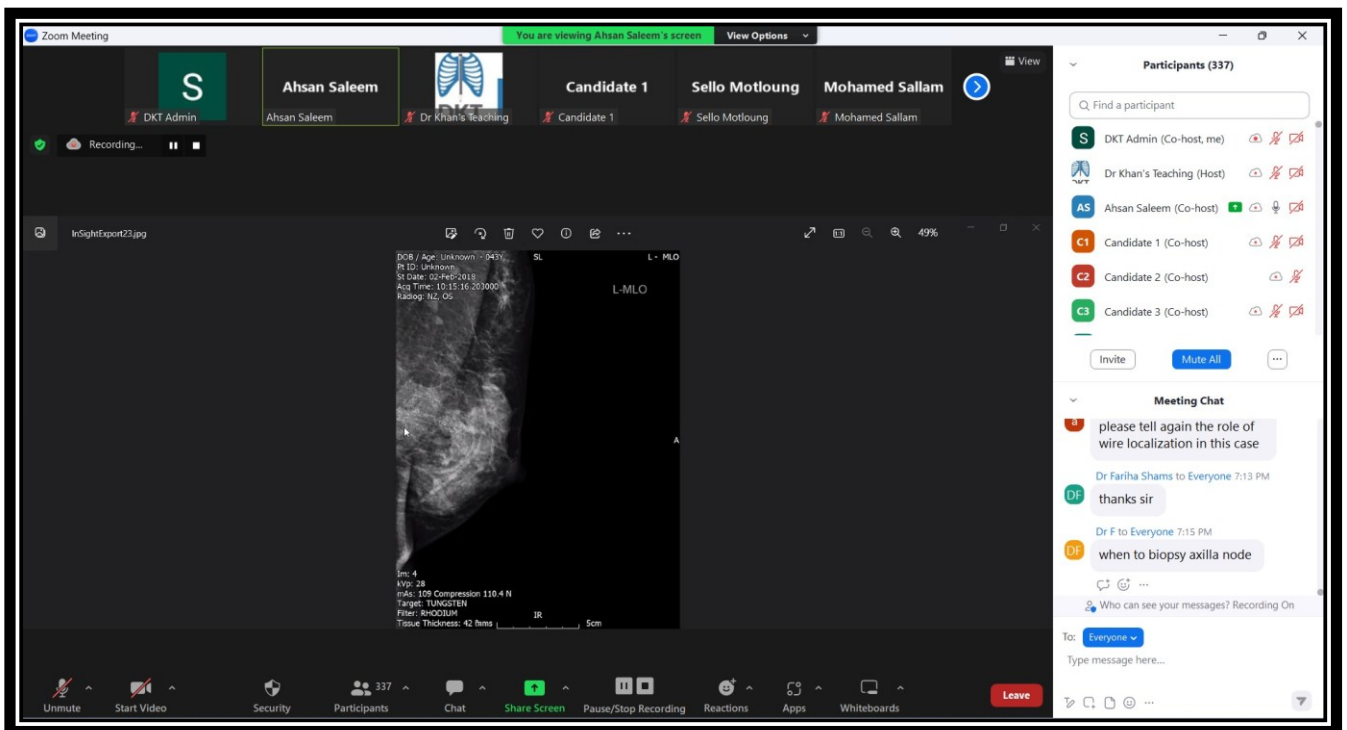
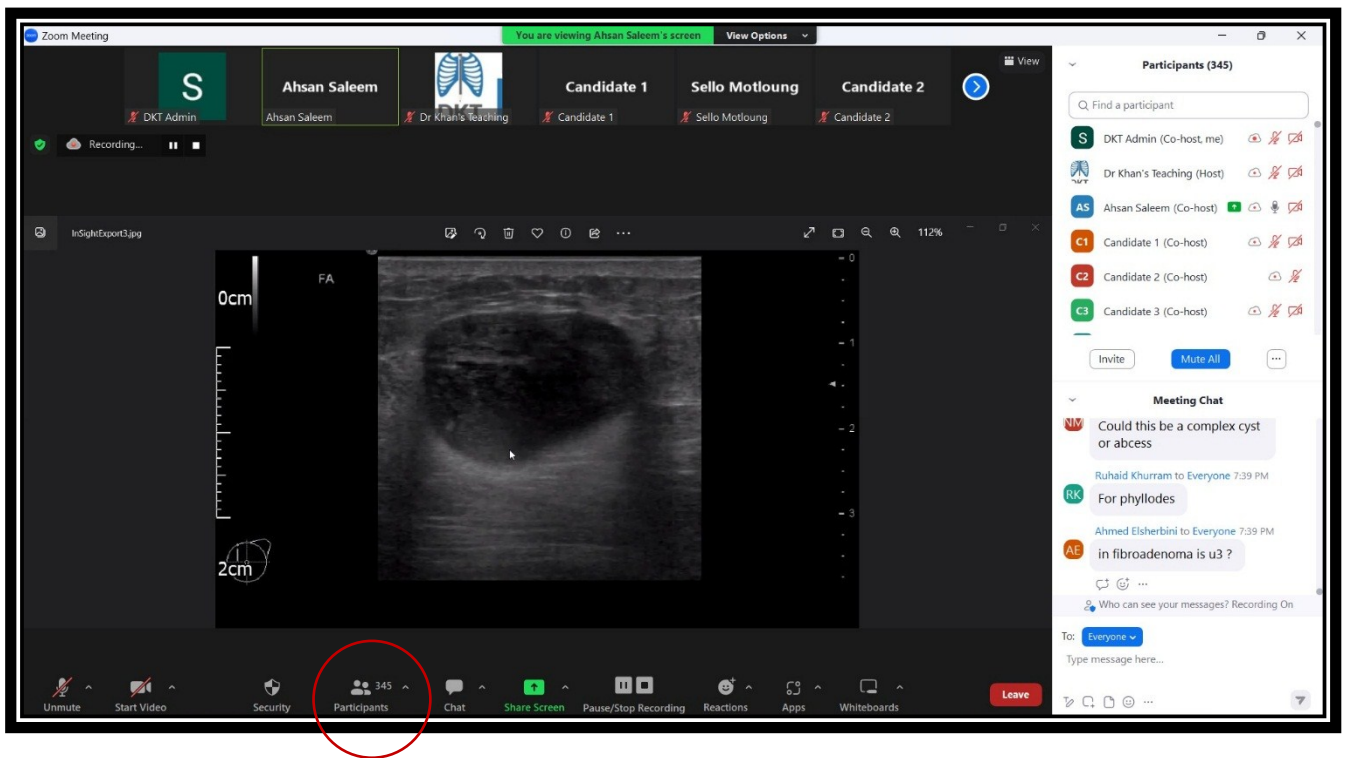
## Testimonials

- Dr Ahsan gave us a nice succinct presentation covering the main theoretical points of how to look at and report a mammogram in a structured way. After this, he showed a good selection of cases covering a spectrum of benign and malignant breast pathologies with good teaching and feedback after the case- he told how each case should be presented in a viva style. I especially liked his comprehensive discussion- he answered each and every question in the chat, and was very patient, and explained thoroughly until all misconceptions were cleared. I feel like I can tackle breast cases now after attending his session (UK).
- I really appreciate Dr. Muhammed Ahsan Saleem taking out the time to give us this lecture (Saudi Arabia).
- Excellent, such a kind and patient teacher, really gave the best teaching and tips and demystified breast imaging for all of the attendees (UK).
- It was just an amazing lecture. I really liked the variety of cases presented in the lecture (India).
- Very exam-focused and useful. It gave me a structure to answer any breast-related question (UK).
- Multiple breast cases were shown on ultrasound and mammography (Saudi Arabia).
- Very crisp comprehensive and much needed session. Thank you! (Pakistan).
- All aspects were elaborated in excellent way explanation was really amazing, great clarity of concepts, covering all areas very well (Pakistan).
- Needed this lecture on breast imaging and instructor was great (Pakistan).
- More than perfect (Saudi Arabia).
- Breast calcification area measurement and guiding surgery were the most valuable aspects (Saudi Arabia).
- Well organized, keep it up, please (Nigeria).
- Excellent lecture and cases (India).
- Case selection, general overview of breast imaging were helpful (UK).
- Informative, very informative (Iraq).

## FRCR 2B Viva - Breast Imaging (Session 21)

- Excellent session (discussion and cases were the best aspects) (Egypt).
- Very informative (Pakistan).
- Great teaching (Pakistan).
- Always an amazing session (Nigeria).
- Very informative and helpful (UAE).
- Valuable session (UK).
- Wow! (Egypt).
- Really helpful teaching (Malaysia).
- Great! Thanks Dr Khan teaching team (Yemen).
- A very, very nice lecture (Pakistan).
- "Very informative. Thanks a lot DKT" (UK).
- Excellent, thank you! (Saudi Arabia).
- Perfect (Jordan).
- Excellent, interactive (Oman).
- Helpful session (Pakistan).
- Very comprehensive session (India).
- Marvellous (Pakistan).
- Very informative (UK).
- Excellent forum for radiology learning. Thank you Dr Khan and his Brilliant team! (Pakistan).
- Great work (Zimbabwe).
- Useful, very useful (Oman).
- Perfect as it is (Saudi Arabia).
- Excellent (UK).
- Useful (Oman).
- Great clarity demonstrated to explain concepts (UK).
- Images are excellent (Türkiye).
- Variability of cases with excellent explanation was great (Oman).
- Exam oriented (UAE).
- All cases were good (Pakistan).
- The information of taking two biopsies in case of more than 4cm suspicious calcifications on mammogram was the most valuable (Egypt).
- The cases and the teacher were amazing (Pakistan).
- Good cases and explanations (UAE).
- Method of approaches and further management was very good, very nice cases (Saudi Arabia).
- He answered all of the audience's questions (Kenya).
- Managerial aspects of breast lesions were awesome (UK).
- Exposure to lots of mammograms was the best aspect (Malaysia).
- Nice teachings points (Pakistan).
- Very good cases and discussion (Pakistan).
- Superb session (India).
- Variety of cases on different imaging modalities was the best (UK).
- Cases, to the point, addressed commonly encountered issues regarding breast imaging.

# FRCR 2B Viva - Breast Imaging (Session 21)



Mammography - The Basic Principles.pptx - Profile 1 - Microsoft Edge  
Ahsan Saleem  
https://ukc-powerpoint.officeapps.live.com/p/PowerPointFrame.aspx?PowerPointView=SlideShowView&ui=en-GB&rs=en-GB&WOPIsrc=https%3a%2f%2fattachments.office.net%3a443%2fowa%2fwopi%2ffiles%2fc95...

## Indications

- I. Routine screening (50 – 70 years) +/- 3 years at either end
- II. One stop patients > 35 years
- III. < 35 years when there is US / biopsy proven cancer but not as primary tool due increased breast density

HOPE

=====XX=====XX=====